

Case 7

Signalment:

A 3 year old Holstein heifer

History:

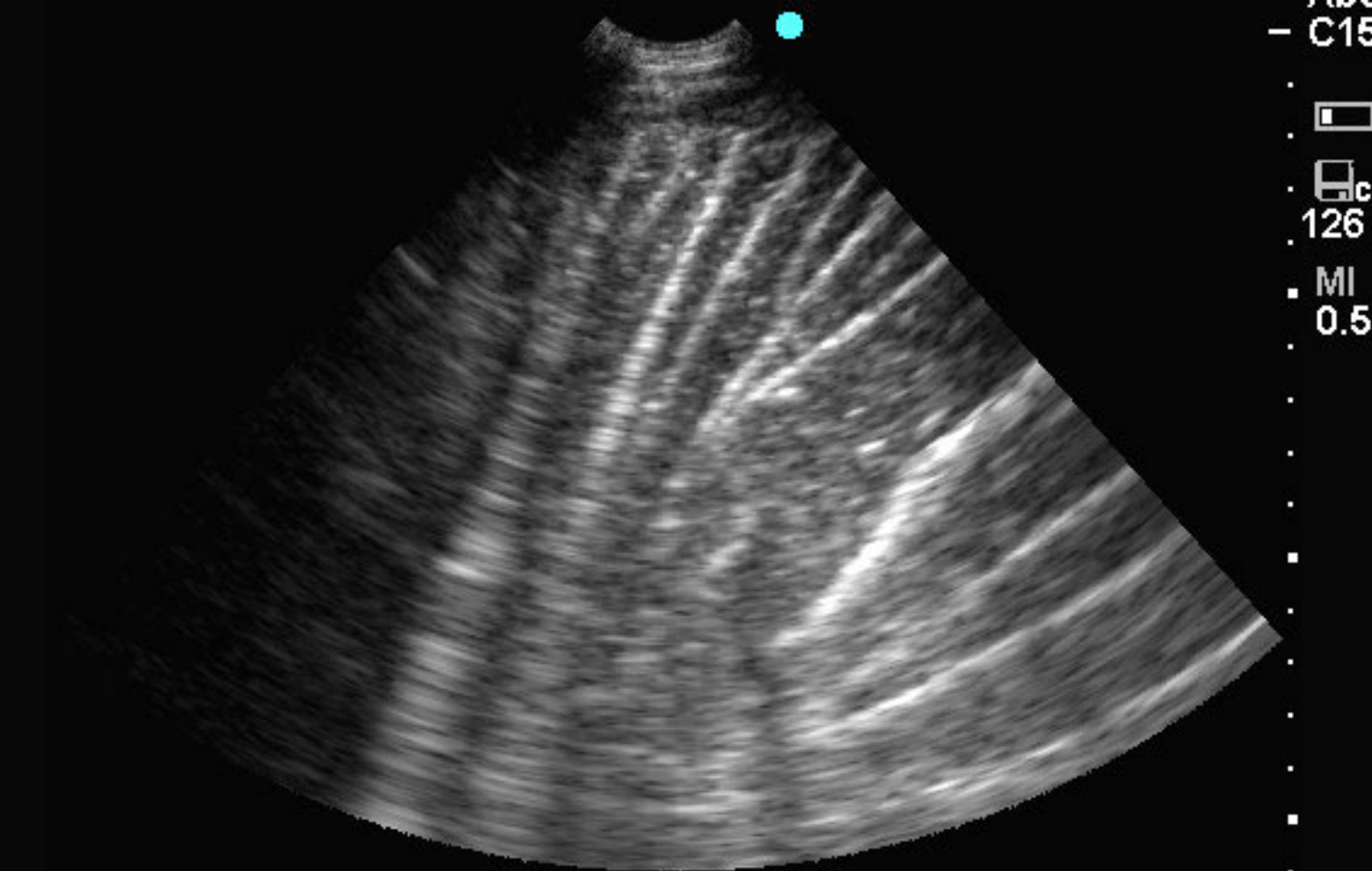
A 1 day history of anorexia, abdominal pain and right flank distension

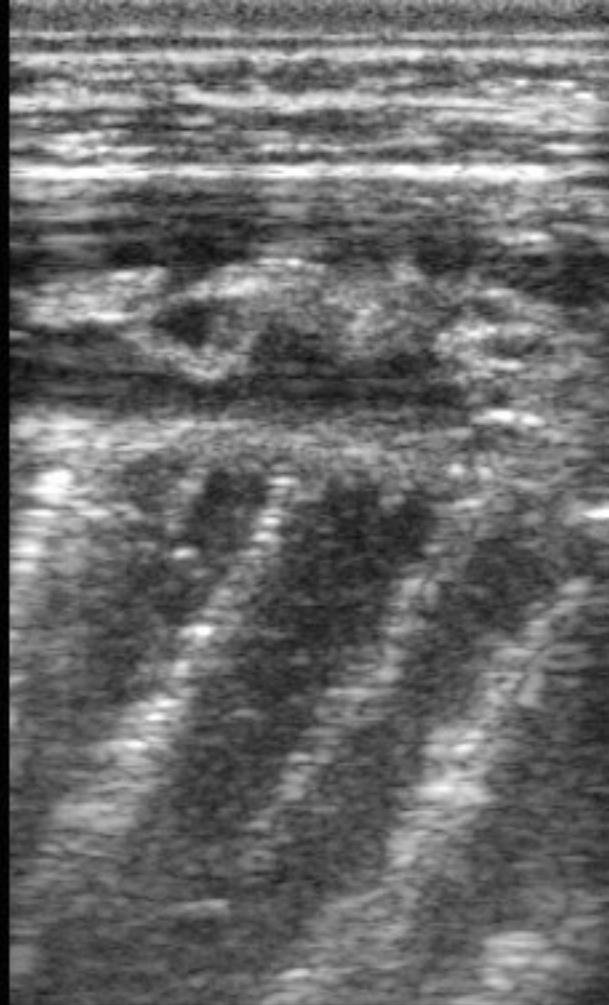
Physical Examination:

A ping was heard over a large area in the right dorsal flank. On rectal palpation a tubular gas distended structure was palpated immediately cranial to the pelvic brim.

Available Study:

Ultrasound images of the ventral abdomen





6.5