

## **Case 2**

### **Signalment:**

A 6 weeks old intact female English Springer Spaniel.

### **History:**

Presented with respiratory distress and abdominal breathing. The referring veterinarian had diagnosed pneumothorax on thoracic radiographs as a part of the evaluation for an intussusception that was successfully treated surgically one week prior to presentation.

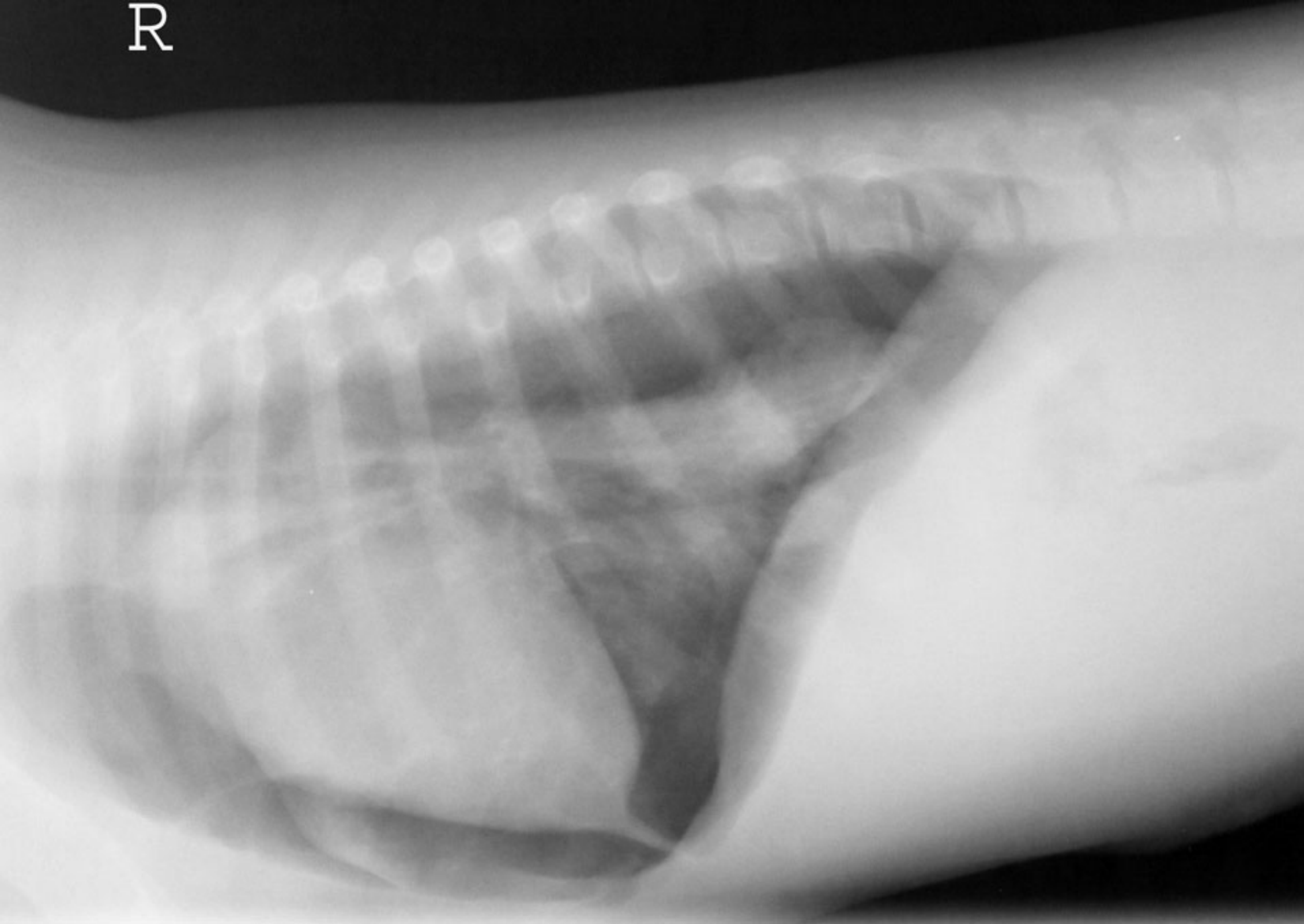
### **Physical Examination:**

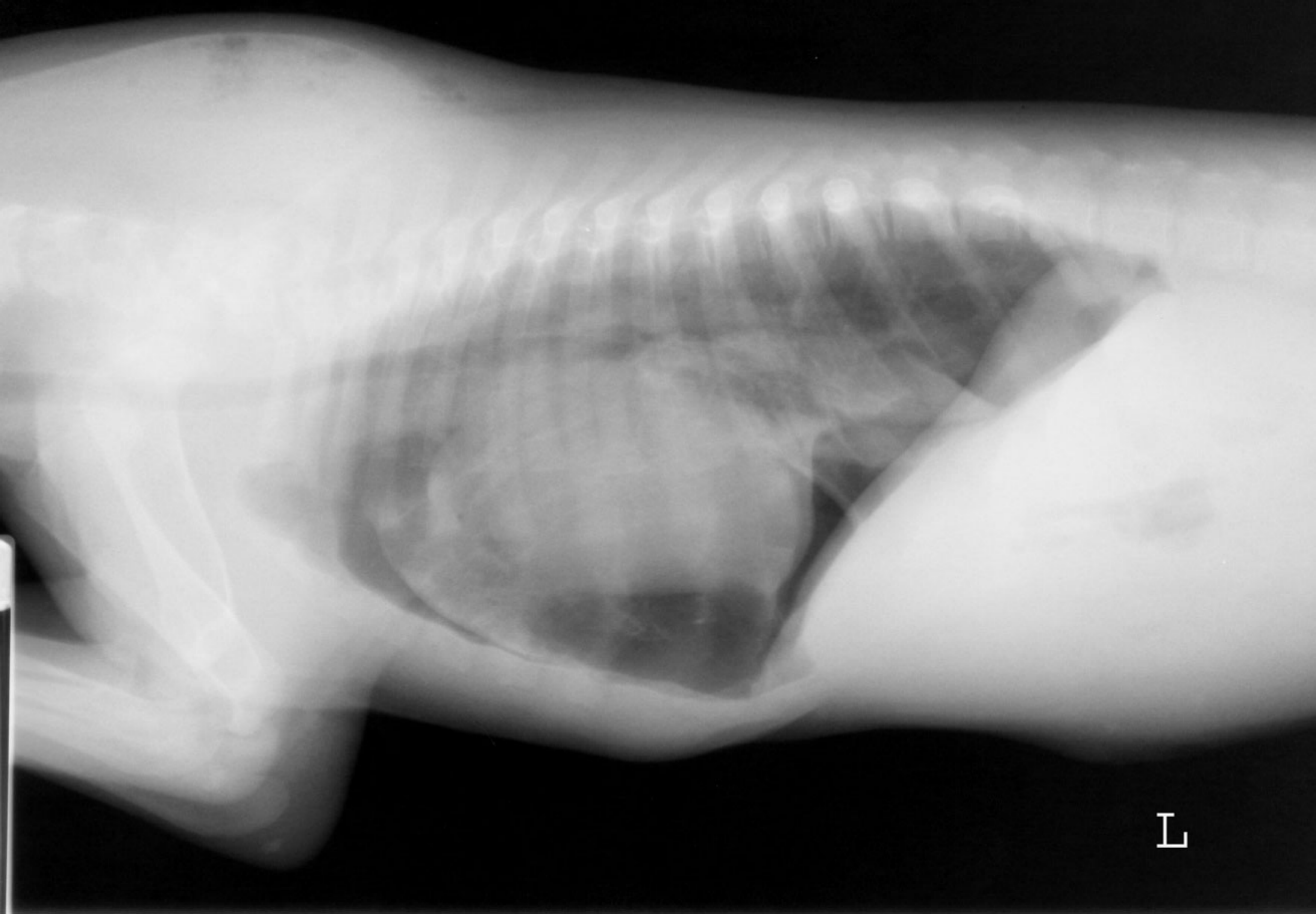
Tachypnea and dyspnea, improvement when placed under an oxygen hood.

### **Available Study:**

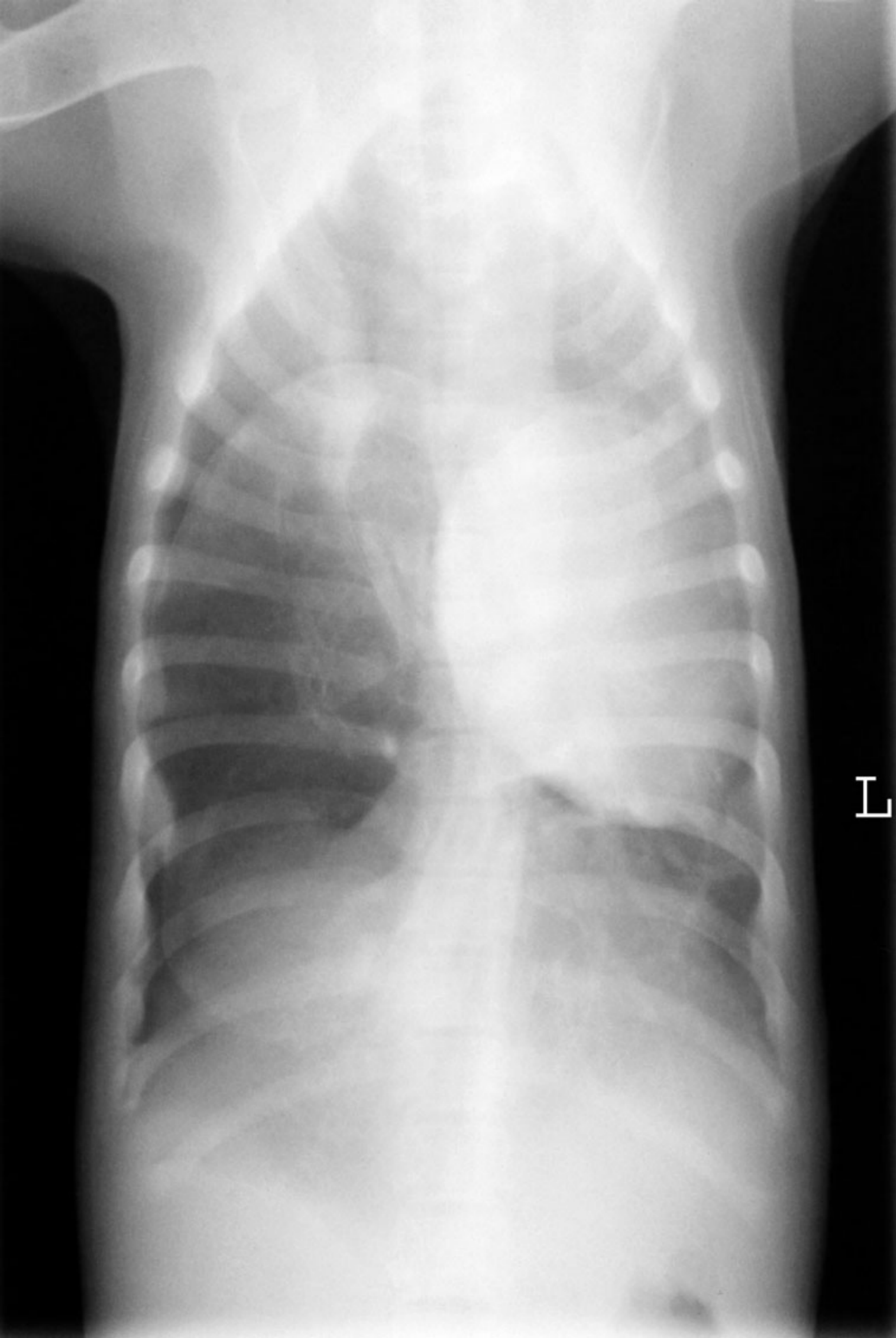
Left and right lateral and dorsoventral projections of the thorax

R





L



L